

## DENTOFACIAL EFFECTS OF FIXED ORTHODONTIC TREATMENT WITH MANDIBULAR SYMPHYSEAL DISTRACTION OSTEOGENESIS AND RAPID MAXILLARY EXPANSION: A ONE-YEAR FOLLOW-UP CASE REPORT

### MANDİBULAR SİMFİZİYAL DİSTRAKSİYON OSTEOGENEZİSİ VE HIZLI MAKSİLLER GENİŞLEME İLE SABİT ORTODONTİK TEDAVİNİN DENTOFASİYAL ETKİLERİ: BİR YILLIK TAKİP VAKA RAPORU

Mehmet Ali Yavan<sup>1</sup>, Nihal Hamamcı<sup>1</sup>, Bilal Ege<sup>2</sup>

<sup>1</sup> Adıyaman University, Faculty of Dentistry, Department of Orthodontics, Adıyaman, Turkey

<sup>2</sup> Adıyaman University, Faculty of Dentistry, Department of Oral and Maxillofacial Surgery, Adıyaman, Turkey

#### ABSTRACT

In this case report, the outcomes of a 17-year-old male patient who underwent fixed orthodontic treatment with rapid maxillary expansion (RME) and tooth-borne mandibular symphyseal distraction osteogenesis (MSDO) were presented. Orthodontic analysis was performed before and after treatment and after one-year follow-up. A significant expansion (+9.9 mm) was observed in mandibular canines after distraction and a 6.1 mm relapse occurred after fixed orthodontic treatment. In conclusion, both the dental and skeletal improvements obtained by the combined use of MSDO, RME, and fixed orthodontic treatment were preserved in the one-year follow-up period.

**Keywords:** Mandibular symphyseal distraction osteogenesis; transverse deficiency; maxillary expansion

Received: 11.09.2023

Accepted: 22.09.2023

Published: 2023.09.2023

#### ÖZET

Bu vaka raporunda, hızlı maksiller genişletme (RME) ve diş kaynaklı mandibular simfiziyal distraksiyon osteogenezi (MSDO) ile sabit ortodontik tedavi uygulanan 17 yaşındaki erkek hastanın sonuçları sunulmuştur. Tedavi öncesi ve sonrası ile bir yıllık takipten sonra ortodontik analiz yapıldı. Distraksiyon sonrası mandibular kaninlerde önemli bir genişleme (+9.9 mm) ve sabit ortodontik tedavi sonrası 6.1 mm nüks meydana geldi. Sonuç olarak, MSDO, RME ve sabit ortodontik tedavinin kombine kullanımı ile elde edilen hem dental hem de iskeletsel gelişmeler bir yıllık takip döneminde korunmuştur.

**Anahtar kelimeler:** Mandibular simfiziyal distraksiyon osteogenezi; transvers darlık; maksiller genişleme

Geliş: 11.09.2023

Kabul: 22.09.2023

Yayın: 2023.09.2023



"This article is licensed under a [Creative Commons Attribution-NonCommercial 4.0 International License](https://creativecommons.org/licenses/by-nc/4.0/) (CC BY-NC 4.0)

RVSR

@6ROD

0 H K P H W \$ O L < D Y D Q \$ G Ö \ D P D Q  
W L W \ ' H S D U W P H Q W R I 2 U W K R G R  
P D L O \ D Y D Q P H K P H W D O L # J P D L O

**Atıf/Citation:** Yavan MA, Hamamcı H, Ege B. Dentofacial effects of fixed orthodontic treatment with mandibular symphyseal distraction osteogenesis and rapid maxillary expansion: a one-year follow-up case report. Dicle Dent J. 2023;24(2): 2- .

## INTRODUCTION

Transverse skeletal deficiency (TSD) is a common clinical problem in orthodontics, predominantly associated with narrow basal and dentoalveolar bone. The diagnosis and treatment of transverse mandibular deficiency has received less attention compared to transverse maxillary deficiency (1). Clinical manifestations of transverse mandibular deficiency include posterior buccal non-occlusion and crowding (2).

Rapid maxillary expansion (RME) is the most common method in the treatment of maxillary TSD (3). In the expansion of transverse mandibular deficiency, Schwarz appliance, lip bumper, and various functional appliances are used in the mixed dentition phase. Although such treatments provide stable outcomes for patients with lingually tipped teeth requiring decompensation, expansion of the anterior region may lead to recurrence and moving teeth out of their supporting alveolar bone may result in compromised periodontium (4).

Mandibular symphyseal distraction osteogenesis (MSDO) has recently emerged as a popular technique for the correction of transverse mandibular deficiency (2). In this technique, the transverse mandibular bone sections are separated so as to

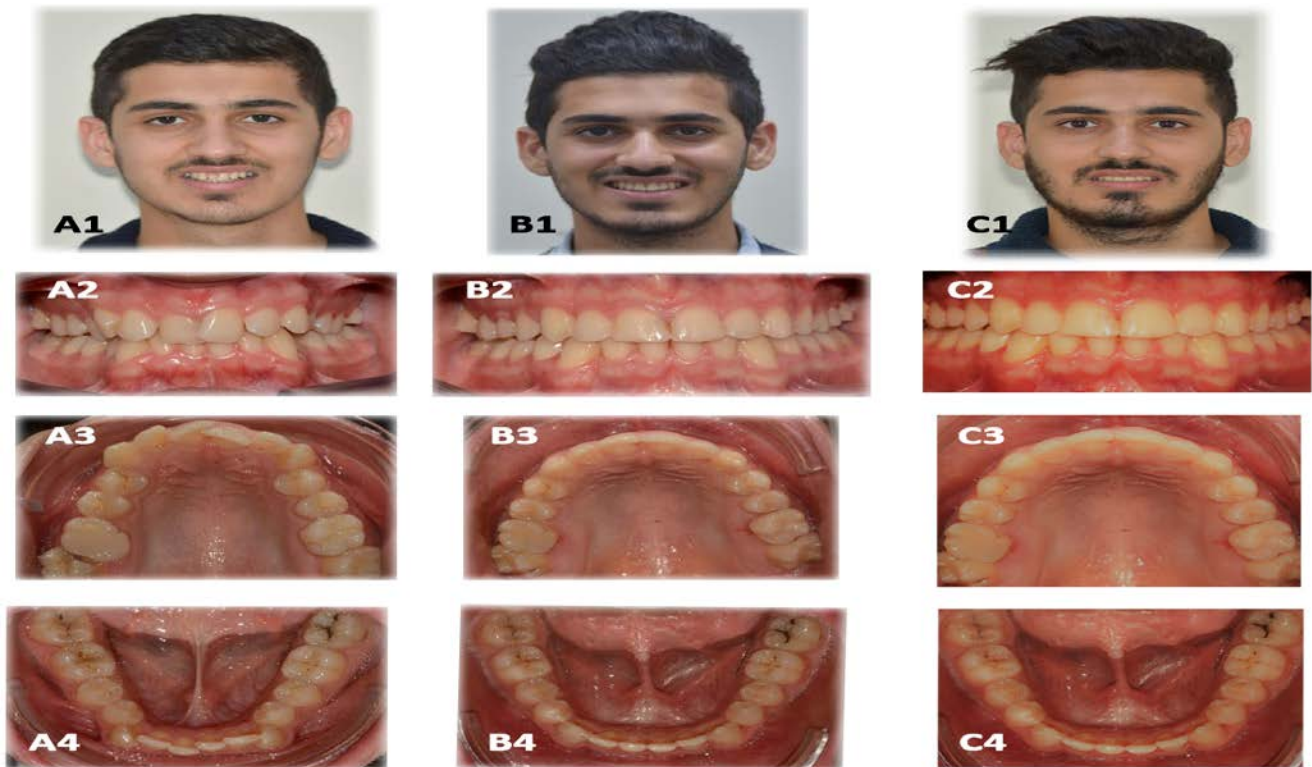
move them away from each other and the newly formed bony cavity is filled as a result of biological activities. The use of MSDO for transverse mandibular deficiency was first described by Guerrero (4). In later years, Del Santo et al. (2) performed MSDO using a tooth and bone-borne device and reported that the device was a remarkable alternative to expansion and orthognathic surgery in the treatment of transverse mandibular deficiency.

Mandibular symphyseal distraction osteogenesis (MSDO) can be performed without compromising aesthetics, with no need for extraction, and no functional or periodontal concerns (5,6). In this report, we present a post-adolescent class II patient who underwent MSDO and RME.

## CASE REPORT

### Diagnosis

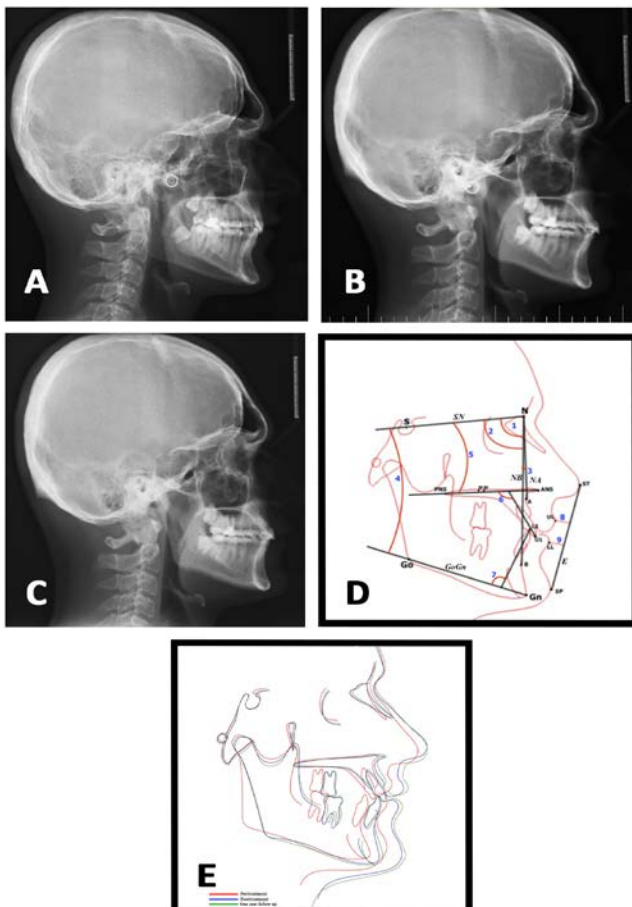
The 17-year-old male patient presented to our clinic with a Class I molar/canine relationship, transversally narrow upper and lower jaw, and a crowding of 7.5 in the mandible and 7 mm in the maxilla according to Hayes-Nance analysis (Figure 1 [A1, A2, A3 and A4]). The patient also had skeletal class II malocclusion (ANB=6.5) (Table 1) (Figure 2A).



**Figure 1.** Extraoral and intraoral photographs of patient. A (1, 2, 3 and 4): Pre-treatment, B (1, 2, 3 and 4): Post-treatment, C: One-year follow-up.

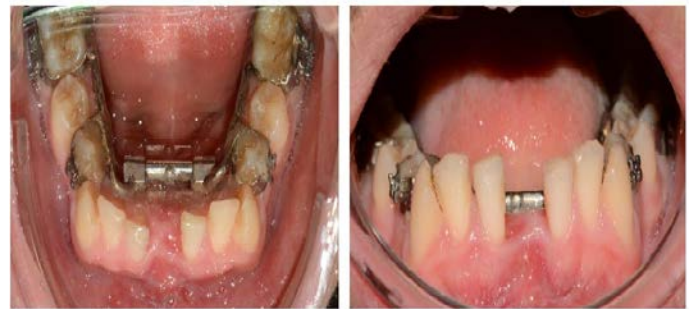**Table 1.** Cephalometric, postero-anterior and maxillary interdental comparisons

Cephalometric measurements	Parameters	Pre-treatment	Post-treatment	One-year follow-up
	SNA (°)	84,8	86,3	86,2
	SNB (°)	78,3	83,6	82,9
	ANB (°)	6,5	2,7	3,3
	SN/GoGn (°)	25	25	24
	SN/PP (°)	14,9	12,6	12
	U1/PP (°)	87,8	111,1	110,8
	IMPA (°)	92	96	95,7
	UL-E (mm)	-9	-8	-7
	LL-E (mm)	-8mm	-9	-8
Pos-tero-ante-	Bicondylar width (mm)	121.1	121.7	121.6
	Bigonial width (mm)	96.5	97	96.7
	Biantegonial width (mm)	86.4	87.4	87.3
Maxillary interdental measure-	U3-U3 (mm)	31	34,6	34,4
	U4-U4 (mm)	27,7	37,6	37,3
	U5-U5 (mm)	36,3	44,2	44
	U6-U6 (mm)	41,6	49,3	49
	U7-U7 (mm)	45,6	52,2	51,6

**Figure 2.** Cephalometric radiographs of patient. A: Pre-treatment, B: Post-treatment, C: One-year follow up, D: Cephalometric measurements: 1.SNA (°), 2. SNB (°), 3. ANB (°), 4. SN/GoGn (°), SN/PP (°), 6. U1/PP (°), 7. IMPA (°), 8. UL-E (mm), 9. LL-E (mm), E: Total cephalometric superimpositions.

### Treatment Process

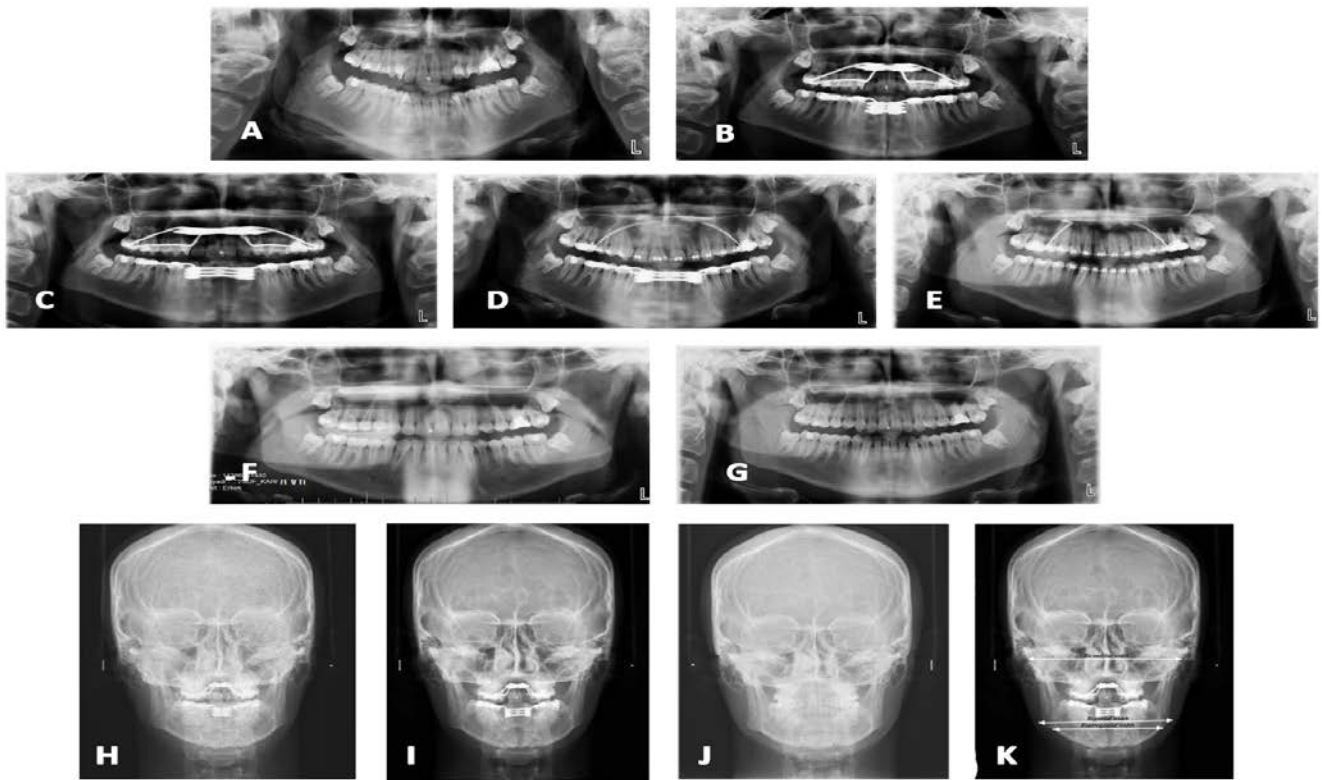
A mandibular symphyseal distraction device was constructed using the classic 13 mm Hyrax screw, which is typically used for RME. The screw was inserted in the lingual side of mandibular incisors. The arms of the screw were bent at the lingual side of the alveolar crest towards mandibular first premolars and molars and then were soldered to the premolar and molar bands. The device was cemented one day before the application of MSDO (Figure 3).

**Figure 3.** Mandibular symphyseal distraction osteogenesis appliance.

Under local anesthesia, a bicortical osteotomy was performed by drawing a straight line between the roots of lower central incisors towards the mandibular base (Figure 4A, 4B and Figure 4H). Following osteotomy, the screw was activated 12 turns and the separation between the osteotomy lines was clearly observed, and then the screw was deactivated and the latent phase was initiated. After the 5-day activation period, the distraction period was initiated.

The screw was activated for a period of 8 days, with 1 mm 4 times per day. During the activation, expansion was detected both clinically and radiologically (Figure 3, Figure 4C and Figure 4I). After completion of the activation period, a 3-month consolidation period was initiated (Figure 4I).





**Figure 4.** Panoramic radiographs of patient. A: Pre-treatment, B: Post-osteotomy, C: Distraction phase, D: Consolidation phase, E: Post-consolidation, F: Post-treatment, G: One-year follow-up, H: Posteroanterior radiograph of post-osteotomy, I: Posteroanterior radiograph of distraction phase, J: Posteroanterior radiograph of post-treatment, K: Posteroanterior measurements.

During the latent phase, a bonded acrylic RME appliance, which was planned to be used for maxillary expansion, was activated (Figure 4C). Maxillary expansion was performed, with 0.5 mm twice per day. After the 10-day activation period, expansion was retained by tying the RME screw. After RME retention, the device was removed and the teeth were cleaned, and a transpalatal arch was applied to teeth upper first molars for retention (Figure 4D).

Fixed orthodontic treatment was applied using a 0.022-inch slot orthodontic bracket (Mini Master Series; American Orthodontics, Sheboygan, WI, USA). The leveling and alignment procedures were performed using superelastic Nickel-Titanium (Ni-Ti) wires (0.012", 0.014", 0.016" round wires followed by 0.016" x 0.022" rectangular wires, respectively). Maxillary and mandibular spaces were closed with 0.017 x 0.025 inch stainless-steel archwire. Following the closure of maxillary and mandibular spaces, elastics (3/16" - 3.5 oz) were used for three months for the correction of Class II molar/canine relationship. Subsequently, 0.018 SS wires were attached to the upper and lower premolars,

and vertical elastics (1/8" 3.5 oz.) were placed between the upper and lower premolars (Figure 4E). The treatment was completed after achieving adequate interdigitation (Figure 1 [B1, B2, B3 and B4]), (Figure 4F, 4J). The fixed orthodontic treatment lasted 18 months in total. To achieve retention, protective Essix plates were used during all day for the first 6 months and then at night only. Cephalometric and posteroanterior measurements are shown in Figure 2D and Figure 4K.

## RESULTS

The administration of MSDO and RME led to significant expansion in mandibular, maxillary, skeletal, and dental arches (Figure 1 [B1, B2, B3 and B4]), (Figure 4J), (Table 1). In the model measurements, a significant expansion (+9.9 mm) was observed in mandibular canines after distraction and a significant relapse (-6.1 mm) occurred after fixed orthodontic treatment (Table 2). In mandibular premolars and molars, the expansion achieved by distraction was preserved after fixed orthodontic treatment. Additionally, significant expansion was observed among maxillary canine, premolars, and molars

following the treatment. On posteroanterior radiography, no change was observed in bicondylar width, while a 0.5 mm increase was detected in bigonial width and a 1 mm increase was noted in biantegonial width (Figure 4I). Cephalometric analysis indicated that the treatment led to an increase of 1.5° in SNA and 5.3° in SNB (Figure 2B). Initially retroclined upper incisors were proclined (U1/SN=23.3°) and reached their ideal position, while an inclination of +5.3° was achieved in lower incisors despite the severe initial crowding. Although the SN/GoGn angle, which shows the inclination of the mandibular and maxillary planes relative to the cranial base, showed no change with treatment, the SN/PP angle showed a 2.3° reduction. The distance to the aesthetic plane decreased by 1 mm in the upper lip and increased by 1 mm in the lower lip.

In the one-year follow-up after treatment, insignificant changes were observed in interdental widths, which confirmed the stability of the expanded basal bone (Figure 1 [C1, C2, C3 and C4], (Figure 4G). Additionally, both posteroanterior (Figure 4J) and cephalometric (Figure 2C) measurements showed that the improvements obtained with treatment were preserved in the follow-up period (Table 1) (Figure 2E).

**Table 2.** Mandibular interdental comparisons

Parameters	Pre-treatment	Af-ter MSDO	Post-treatment	One-year fol-low-up
L3-L3	22,6	32,5	26,4	26,4
L4-L4	24,2	30,5	33,2	33,1
L5-L5	31,5	39,4	39	38,9
L6-L6	37,8	43,6	44,5	43,8
L7-L7	40,8	46,4	45,7	45,2

## DISCUSSION

The effect of dental expansion on the basal bone may be greater in tooth-borne mandibular symphysis distraction devices than in tooth and bone-borne devices; however, there is no need for secondary surgery in tooth-borne devices, unlike in bone and tooth and bone-borne devices (7). In the case presented, a tooth-borne device was used due to its practicality and cost-effectiveness.

During the active period of distraction osteogenesis, regeneration of the newly formed bone is

directly affected by mechanical and biological forces (8,9). Previous clinical studies (2,5,10,11) reported that disproportionate and mobile incisions may create larger spaces in the alveolar region. In the present study, MSDO device positioning and symphyseal incision were planned after taking these probabilities into consideration.

The key advantage of the distraction osteogenesis is the gradual expansion of the skeleton and periosteum with simultaneous expansion of the functional soft tissue matrix including masticatory muscles, subcutaneous tissues, and skin. This soft tissue expansion also ensures little or no skeletal recurrence. A consolidation period of at least 3 months is required for mandibular expansion and the exact duration of this period is determined based on radiographic imaging of the regeneration of cortical bone. In our patient, radiolucency that was caused by distraction and was detected on panoramic radiography at month 3 decreased with the formation of the new bone, and after the treatment, it almost regained its pre-treatment radiopacity.

In our patient, the lower incisors moved towards the distraction site after symphyseal distraction. Although there are studies suggesting that displacing the incisors before obtaining the first radiological signs of new bone formation in the distraction site may cause bone and periodontal diseases in the incisors, (5,12,13) some other studies indicated that the displacement of the incisors by the impact of optimal orthodontic forces at the beginning of the consolidation period facilitate bone-related activities in the distraction site and that orthodontic tooth movement increases the ossification rate (14,15).

In the case presented, the analysis of posteroanterior radiographs indicated a 0.5 mm increase in bigonial width and a 1 mm increase in biantegonial width, although no change was observed in bicondylar width. These findings were consistent with those reported by Del Santo et al. (2). Additionally, the analysis also showed that the width of the mandibular arch in the symphyseal region increased significantly, while the ramal and gonial regions of the condyle showed minimal displacement. This mandibular expansion is

a triangular pattern with the condyle at the apex and the symphysis at the base (16,17). Malkoc et al.16 detected a significant reduction in bicondylar width (0.7 mm) after distraction and attributed this reduction to the tooth and bone-borne distraction device and its position. In a previous finite element method (FEM) study, in a similar way to our study, anteroposterior evaluation showed that the greatest expansion was achieved in the symphyseal region and the expansion gradually decreased from anterior to posterior (17).

In our patient, the model measurements performed immediately after the distraction indicated that the mandibular intercanine distance increased by 9.9 mm, the inter-first premolar distance increased by 6.3 mm, the inter-second premolar distance increased by 7.9 mm, the inter-molar distance increased by 5.8 mm, and the inter-second molar distance increased by 5.6 mm. These findings implicate that the interdental distances decreased gradually after the application of MSDO, beginning from the canines closest to the symphysis to the farthest second molars. Del Santo et al. reported that MSDO produced an inverted V-shaped expansion with its base in the anterior region and its tip in the posterior region.<sup>2</sup> This finding is similar to our findings and to those reported by Gunbay et al.<sup>18</sup> and Malkoc et al.<sup>(16)</sup>.

In our patient, the model measurements performed after distraction showed that the fixed orthodontic treatment produced a significant relapse in mandibular canines (-6.1 mm) as well as a significant expansion in both first premolars (+3.3 mm) and first molars (+0.9 mm). It is commonly known that after MSDO, the diastemas in the intercanine region should be closed by leveling the teeth in an ideal way. During this closure, the incisors and canines can be lingually displaced in line with the form of the archwire. On the other hand, the interdental expansion achieved by fixed orthodontic treatment in the premolar and molar regions is considered to be due to the wide arch forms (19,20).

In our report, cephalometric analysis showed that the maxilla and mandible moved signifi-

cantly anteriorly with treatment. There are some studies in the literature reporting that RME resulted in spontaneous anterior movement of the soft tissue point A in the maxilla (21-23). Some other studies, in a similar way to our study, reported on the translation effect of MSDO on the anterior movement of the mandible (7,18). In our patient, initially retroclined upper incisors were proclined with fixed orthodontic treatment ( $U1/SN=23.3^\circ$ ) and reached their ideal angle. In addition, a significant anterior movement ( $SNB, +5.3^\circ$ ) occurred due to the effect of increased overjet caused by the proclination of the upper incisors and the use of Class II elastics despite the completion of the growth and development at point B. On the other hand, no significant change was observed in the inclination of the mandibular plane relative to the cranial base ( $SN/GoGn$ ), which was consisted with the literature (2,18,24).

Our findings also indicated that post-distraction orthodontic treatment resolved the crowding predominantly by moving the teeth towards the newly formed bone in the distraction site. Proclination of mandibular incisors during MSDO is a clinical problem, as shown by Del Santo et al (7). This proclination may be due to the distraction pattern of the tooth and bone-borne device, the absence of lip pressure during distraction and consolidation periods, and the application of fixed orthodontic treatment (4,7). In our patient, a  $5.3^\circ$  proclination was achieved in initially retroclined lower incisors despite the application of MSDO.

In the one-year follow-up after treatment, insignificant changes were observed in interdental widths, which confirmed the stability of the expanded basal bone. Additionally, both postero-anterior and cephalometric measurements showed that the improvements obtained with treatment were preserved in the follow-up period. In a similar way, studies investigating long-term skeletal and dental outcomes of MSDO also reported that permanent transversal expansion can be achieved and the basal bone structure can be preserved for a long period of time by the application of MSDO (2,18).



## CONCLUSIONS

The results indicated that MSDO is a promising and clinically applicable technique for mandibular expansion. Additionally, the interdental expansion achieved by MSDO was preserved after the treatment and during the one-year follow-up period. On the other hand, the skeletal class II malocclusion in our patient was corrected with the significant mandibular translation achieved by combined use of MSDO, RME, and fixed orthodontic treatment despite the completion of the growth and development period.

## REFERENCES

1. Chung CH, B Font. Skeletal and dental changes in the sagittal, vertical, and transverse dimensions after rapid palatal expansion. *Am J Orthod Dentofacial Orthop.* 2004;126(5):569-75.
2. Del Santo M, Guerrero CA, Bushang PA, English JD, Samchukov ML, et.al. Long-term skeletal and dental effects of mandibular symphyseal distraction osteogenesis. *Am J Orthod Dentofacial Orthop.* 2000;118:485-93.
3. Sari Z, Uysal T, Usumez S, Basciftci FA. Rapid maxillary expansion. Is it better in the mixed or in the permanent dentition? *Angle Orthod.* 2003;73:654-61.
4. Guerrero CA, Bell WH, Contasti GI, Rodriguez AM. Mandibular widening by intraoral distraction osteogenesis. *Br J Oral Maxillofac Surg.* 1997;35:383-92.
5. Constanti G, Guerrero C, Rodriguez AM, Legan HL. Mandibular widening by distraction osteogenesis. *J Clin Orthop.* 2001;35:165-73.
6. Kewitt GF, Van Sickels JE. Long-term effect of mandibular midline distraction osteogenesis on status of the temporomandibular joint, teeth, periodontal structures, and neurosensory function. *J Oral Maxillofac Surg.* 1999;57:1419-25.
7. Del Santo M, English JD, Wolford LM, Gandini LG. Midsymphyseal distraction osteogenesis for correcting transverse mandibular discrepancies. *Am J Orthod Dentofacial Orthop.* 2002;121:629-38.
8. Bell WH, Harper RP, Gonzalez M, Cherkashin AM, Samchukov ML. Distraction osteogenesis to widen the mandible. *Br J Oral Maxillofac Surg.* 1997;35:11-9.
9. Grayson BH, Santiago PE. Treatment planning and biomechanics of distraction osteogenesis from an orthodontic perspective. *Semin Orthod.* 1999;5:9-24.
10. Hollis BJ, Block MS, Gardiner D, Chang A. An experimental study of mandibular arch widening in the dog using distraction osteogenesis. *J Oral Maxillofac Surg.* 1998;56:330-8.
11. Duran I, Malkoc S, Iseri H, Tunali M, Tosun M, Kucukkolbasi H. Microscopic evaluation of mandibular symphyseal distraction osteogenesis. *Angle Orthod.* 2006;76:369-74.
12. Conley R, Legan H. Mandibular symphyseal distraction osteogenesis: diagnosis and treatment planning considerations. *Angle Orthod.* 2003;73:3-11.
13. Guerrero CA, Bell WH, Contasti GI, Rodriguez AM. Intraoral mandibular distraction osteogenesis. *Semin Orthod.* 1999;5:35-40.
14. Cope JB, Samchukov ML. Regenerate bone formation and remodeling during mandibular osteodistraction. *Angle Orthod.* 2000;70:99-111.
15. Liou EJ, Polley JW, Figueroa AA. Distraction osteogenesis: the effects of orthodontic tooth movement on distracted mandibular bone. *J Craniofac Surg.* 1998;9:564-71.
16. Malkoç S, İseri H, Karaman Aİ, Mutlu N, Küçükkolbaşı H. Effects of mandibular symphyseal distraction osteogenesis on mandibular structures. *Am J Orthod Dentofacial Orthop.* 2006;130:603-11.
17. Başçiftçi F, Korkmaz H, İseri H, Malkoç S. Biomechanical evaluation of mandibular midline distraction osteogenesis by using the finite element method. *Am J Orthod Dentofacial Orthop.* 2004;125:706-15.
18. Gunbay T, Akay MC, Aras A, Gomel M. Effects of transmandibular symphyseal distraction on teeth, bone, and temporomandibular joint. *J Oral Maxillofac Surg.* 2009;67:2254-65.
19. Fuck LM, Drescher D. Force systems in the initial phase of orthodontic treatment—a comparison of different leveling arch wires. *J Orofac Orthop.* 2006;67:6-18.
20. Baldwin PD, Pender N, Last KS. Effects of tooth movement of force delivery from nickel-titanium archwires. *Eur J Orthod.* 1999; 21: 481– 489.
21. Cross DL, McDonald JP. Effect of rapid maxillary expansion on skeletal, dental, and nasal structures: a postero-anterior cephalometric study. *Eur J Orthod.* 2000;22:519-28.
22. Lagravère MO, Carey J, Heo G, Toogood RW, Major PW. Transverse, vertical, and anteroposterior changes from bone-anchored maxillary expansion vs traditional rapid maxillary expansion: a randomized clinical trial. *Am J Orthod Dentofacial Orthop.* 2010; 137:304.e1-12.
23. Velazquez P, Benito E, Bravo LA. Rapid maxillary expansion. A study of the long-term effects. *Am J Orthod Dentofacial Orthop.* 1996;109:361-7.
24. Seeberger R, Kater W, Davids R, Thiele OC, Edelmann B, et. al. Changes in the mandibular and dento-alveolar structures by the use of tooth borne mandibular symphyseal distraction devices. *J Craniomaxillofac Surg.* 2011;39:177-81.